

# Possibilities of Application of Low-Temperature Air Pressure in the Treatment of Burn Wounds

Evgenii Zinovev,<sup>a,b</sup> Vasilii Tsygan,<sup>a</sup> Marat Asadulaev,<sup>b</sup> Oleg Borisov,<sup>b</sup>  
Ivan Lopatin,<sup>b,\*</sup> Sergey Lukianov,<sup>b</sup> Ilia Artsimovich,<sup>b</sup> Moisei Paneiakh,<sup>b</sup>  
Denis Kostiaikov,<sup>a</sup> Sergey Kravtsov,<sup>a</sup> & Kamal Osmanov<sup>a</sup>

<sup>a</sup>Military Medical Academy, S.M. Kirova, St. Petersburg, Russia; <sup>b</sup>St. Petersburg State Pediatric Medical University, St. Petersburg, Russia

\*Address all correspondence to: Ivan Lopatin, St. Petersburg State Pediatric Medical University, St. Petersburg, Russia; Tel.: +7 (812) 295-06-46, Fax: (812) 295-40-85, E-mail: lopatin124@gmail.com

**ABSTRACT:** We present results of an experimental evaluation of implementation effectiveness of low-temperature air plasma of an atmospheric pressure arc discharge for treatment of third-degree skin burns in laboratory rats. Thermal skin burns were produced by our own original method, and efficacy was assessed daily. We found that the use of low-temperature air plasma of an atmospheric pressure arc discharge permits accelerated final wound healing by 49% ( $p < 0.05$ ) and reduces incidence of purulent inflammation by 45.5% ( $p < 0.01$ ).

**KEY WORDS:** deep skin burns, low-temperature air plasma of atmospheric pressure arc discharge, plasma generator, skin restoration, reparative regeneration, combustiology, surgical treatment

## I. INTRODUCTION

According to a March 2018 World Health Organization assessment, 180,000 annual deaths are the result of burns, with the vast majority of events occurring in low- and middle-income countries. Nonfatal burn injuries occur mainly at home and in the workplace and are one of the main causes of morbidity.<sup>1–3</sup> The provision of assistance to this category of victims requires a multidisciplinary approach, taking into account pathogenesis of burn disease and features of the wound process that are typical for this type of damage.<sup>4</sup>

A system of active surgical treatment for seriously ill persons is recognized as generally accepted,<sup>5,6</sup> but this approach has a number of disadvantages including a relatively high frequency of lysis with autodermotransplants, inevitability of long-term treatment and frequent dressings under anesthesia, high incidence of local and common infectious complications and duration of the rehabilitation period.<sup>7</sup>

In addition to the traditional methods for restoring the skin of the victims with burns, a variety of techniques for treating wounds such as ultraviolet radiation, ultrasound, and magnetic laser therapy are based on various physical factors.<sup>8</sup> Such methods achieve antibacterial proliferative effects that stimulate capillary blood flow and tissue metabolism and improve microcirculation.<sup>9</sup>

A perspective physical method of wound-surface treatment is the use of plasma, which uses an ionized high-temperature gas consisting of charged particles, free electrons, ions, chemical rad-

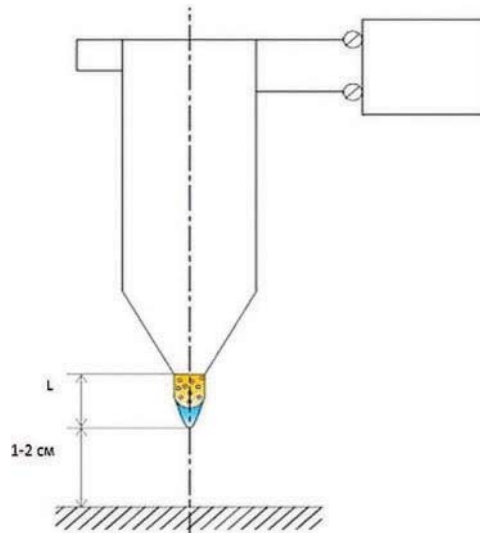
icals, infrared light, and ultraviolet radiation.<sup>4</sup> In addition to temperature, electromagnetic fields are an important factor in treatment with plasma components, but this can also damage the structure of cytoplasmic membranes of microorganisms and viruses, targeting their vital systems.<sup>10</sup>

The advantage of low-temperature air plasma of an atmospheric pressure arc discharge, which produces complex effects (antimicrobial, hemostatic, and proliferative) is recognized as promising for optimizing the processes of reparative regeneration during the wound process. In a device that we developed,<sup>11</sup> the operating temperature of generated plasma varies around  $\pm 50^{\circ}\text{C}$  and does not damage viable tissues. An important feature of the proposed method is the use of atmospheric air as the working gas. This method also ensures achievement of stable hemostasis without high-temperature damage of surrounding tissues, which can occur with electro- or argon-plasma coagulation. We achieve hemostasis by accelerating aggregation of platelets and formation of a fibrin clot. Treatment of the wound surface with a plasma torch not only sterilizes the surface but also protects against environmental microbial contamination that can result from the film formed from the nanolayer of coagulated protein.<sup>12</sup>

## II. MATERIALS AND METHODS

We performed the experiment using 44 male Wistar Kyoto rats weighing 230–250 g. Total experiment duration was 40 d. All manipulations with animals were performed under inhalational anesthesia in aseptic conditions, following provisions of the Helsinki Declaration of the World Medical Association.

Third-degree skin burns were produced according to our method, depicted in Fig. 1. An iron plate with a constant temperature of  $100^{\circ}\text{C}$  was applied to the skin of the rat through wet gauze for 10 s, and plasma was generated by our original device (Fig. 2). The developed



**FIG. 1:** Operation of a beam of low-temperature air plasma of an atmospheric pressure arc discharge



**FIG. 2:** Development of plasma-generation device

plasma generator, with a 100-mm torch diameter, allows a combined direct action of the plasma substance on the surface with the therapeutic effect of nitric oxide.

All animals were divided into four groups (11 individuals in each group), taking into account choice of method for local treatment. The first group (control) had no treatment, the second were treated with wet-drying dressings using solutions of antiseptics, the third group had bandages applied with the multicomponent antibacterial ointment levomekol, and the fourth group's postoperative wounds were treated with a low-temperature atmospheric low-pressure plasma, with the generation of a film nanolayer.

On a daily basis, we carried out effectiveness evaluation of the analyzed methods of wound treatment. We used the planimetric method proposed by L.N. Popova to determine wound area and calculated healing index using the formula developed by Fenchin in 1979

$$\frac{(S - S_n) \times 100}{S \times T},$$

where  $S$  is the wound area at the previous measurement of 2 mm,  $S_n$  is the area of the wound at the given measurement of 2 mm, and  $T$  is the interval between measurements in days.

Selection of biopsy specimens for histological examination was performed on the second, ninth, 15th, 21st, 35th, and 40th days of treatment. We processed obtained results in accordance with the generally accepted method of variational statistics, and the reliability criterion was  $p < 0.05$ .

### III. RESULTS AND DISCUSSION

We found that the local treatment agents produced different wound-healing effects. Results of a comparative evaluation of the time required for final healing of experimental wounds, depending on treatment method, are given in Table 1. Table 2 shows the frequency of purulent complications that occurred during the wound process, and the data in Table 3 allow us to conclude that the smallest scar area occurring after final healing of experimental wounds was observed in the group of animals treated with the use of low-temperature air plasma of the arc discharge (the fourth group).

**TABLE 1:** Planimetric evaluation of wound-healing processes in study groups

Group	Treatment time (d)
First	35 ± 2.5
Second	28 ± 1.7*
Third	24 ± 2.1*
Fourth	18 ± 1.2†

\*Differences from first group.

†Compared to first, second, and third groups;  $p < 0.05$ .

**TABLE 2:** Frequency of purulent complications in wound process of study groups

Group	Frequency of infectious complications (%)
First	54.5 ± 1.8
Second	27.2 ± 2.3*
Third	18.2 ± 1.2†
Fourth	9%‡

\*Differences from first group.

†Compared to first and second groups.

‡Compared to first, second, and third groups;  $p < 0.05$ .

**TABLE 3:** Area of scar formed after wound healing of study groups

Group	Rumen area (cm <sup>2</sup> )
First	12 ± 1.4
Second	9 ± 0.8
Third	7 ± 1.1*
Fourth	4 ± 0.5†

\*Differences from first group.

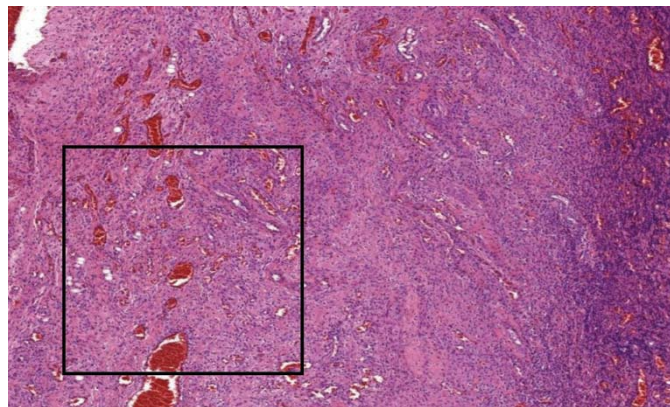
†Compared to first, second, and third groups;  $p < 0.05$

We revealed that during treatment of burn wounds by low-temperature air plasma of atmospheric pressure arc discharge, final healing begins on the 18th day of observation, which is 49% faster ( $p < 0.05$ ) than that in the first group of animals (no treatment). When dressings with solutions of antiseptics and levomecol (third group) were used, the defect contraction was marked on days 28 and 24 of the study, respectively. In the control group (no treatment), wounds healed independently after 35 d of observation.

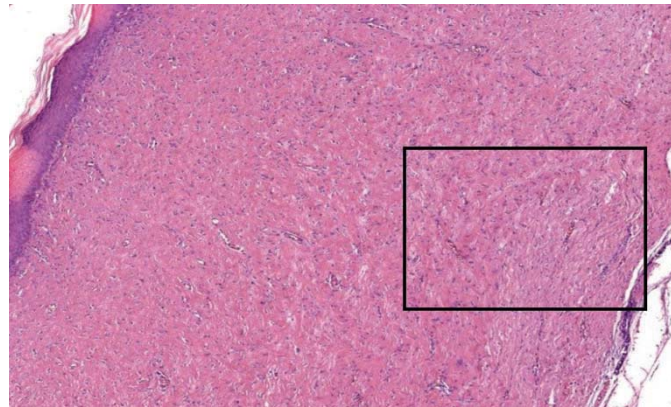
Burn wounds are obligately contaminated with a wide spectrum of pathogenic microflora that cause a pronounced inflammatory reaction and a consequently complicated course of the wound process. During the experiment, nine cases of purulent inflammation of various degrees of severity were noticed in the observation groups.

In a histological study of wound biopsy specimens, we found that in animals receiving no treatment, by the 15th day of observation of the experimental wound area, a large wound defect with abundant purulent exudate on its surface was present. The use of wet-drying dressings with solutions of antiseptics and levomekol ointments did not significantly optimize the course of the reparative regeneration process. In the first group, examined on the 15th day of the study, the wound was represented by a large defect, at the bottom of which fibrous connective tissue was located that contained diffuse, mildly expressed lymphohistiocytic infiltration and focal impurity of neutrophilic leukocytes.

The greatest intensity of the early processes of reparative regeneration was noted in the group of animals whose wounds were treated with an air plasma stream. Histological analysis of biopsy specimens taken on day 3 showed the wound surface to be represented by a thin strip of 50–70-nm thick formed film from the coagulated protein of the wound exudate (Fig. 3). By the 15th day of the experiment, the nanofilm on the surface of the wound completely broke away. On the periphery of the wound, the epithelial shaft was actively visualized and spread to the mature granulation tissue. No edema formed, and weakly expressed, diffuse, lymphocytic, neutrophilic inflammatory infiltration occurred (Fig. 4).



**FIG. 3:** Rat skin in fourth group on day 3 after third-degree burn. Visible are areas of protein nanofilms and dermis with moderate leukocyte infiltration. Stained with hematoxylin eosin



**FIG. 4:** Rat skin in fourth group on day 15 after third-degree burns. Visible is mature granulation tissue with active marginal epithelialization. Stained with hematoxylin eosin

Thus, implementation of low-temperature air plasma arc discharge of atmospheric pressure, compared to traditional treatment methods of burn wounds, optimizes the course of the wound process and as a result reduces healing time and area of the scar. The thin biological film formed from the nanoscale of the coagulated proteins of the wound exudate of the protein that was formed during treatment by plasma flow on the wound surface proved to be an effective barrier—an epidermal prosthesis so to speak—protecting the wound from drying out and secondary contamination.

#### IV. CONCLUSIONS

Our study showed that the use of low-temperature air plasma of an atmospheric pressure arc discharge is a promising technique for burn treatment that optimizes the wound process in the area of skin defects, including that of deep burns. The application of this technique accelerates the process of wound regeneration by 49% and reduces the area of formed scar by 67% ( $p < 0.05$ ). Treatment of the wound with low-temperature air plasma of the atmospheric pressure arc discharge after early surgical necrectomy allows generation of a 50–70-nm nanofilm from the coagulated protein layer of wound exudate as well as cell fragments that are impermeable to microorganisms and have selective vapor and moisture permeability on the wound surface. Plasma treatment and film formation reduces contamination of wounds by pathogenic microflora and prevents drying out, thus reducing frequency of purulent complications.

#### REFERENCES

1. Burd A, Tor C. Allogenic skin in the treatment of burns. *Clin Dermatol.* 2005;23(4):376–87.
2. Dantzer E, Queruel P, Salinier L, Palmier B, Quinot JF. Integra, a new surgical alternative for the treatment of massive burns. Clinical evaluation of acute and reconstructive surgery: 39 cases. *Ann Chirurgie Plast Esthet.* 2001;46(3):173–89.

3. Burdge JJ, Katz B, Edwards R, Ruberg R. Surgical treatment of burns in elderly patients. *J Trauma*. 1988;28(2):214–7.
4. Farin G, Grund KE. Technology of argon plasma coagulation with particular regard to endoscopic applications. *Endoscop Surg Allied Technol*. 1994;2(1):71–7.
5. Hyakusoku H, Orgill DP, Teot L, Pribaz JJ, Ogawa R, editors. *Color atlas of burn reconstruction surgery*. 1st ed. London: Springer; 2010.
6. Klasen HJ. Historical review of the use of silver in the treatment of burns. I. Early uses. *Burns*. 2000;26(2):117–130.
7. Herndon DN, Curreri PW, Abston S, Rutan TC, Barrow RE. Treatment of burns. *Curr Problems Surg*. 1987;24(6):347–97.
8. Weltmann KD, Kindel E, Brandenburg R, Meyer C, Bussiahn R, Wilke C, Von Woedtke T. Atmospheric pressure plasma jet for medical therapy: Plasma parameters and risk estimation. *Contrib Plasma Phys*. 2009;49(9):631–40.
9. Pedroso J, Gutierrez M, Volker KW. Comparative thermal effects of J-plasma, monopolar, argon and laser electrosurgery in a porcine tissue model. *J Minimally Invasive Gynecol*. 2014;21(6):S59.
10. Reuter S, Winter J, Iseni S, Peters S, Schmidt-Bleker A, Dünnebier M, Schäfer J, Foest R, Weltmann K-D. Detection of ozone in a MHz argon plasma bullet jet. *Plasma Source Sci Technol*. 2012;21(3):1–10.
11. Borisov OV, inventor. Tissue tolerable plasma generator and method for the creation of protective film from the wound substrate. Switzerland patent 2017054534. 2002 Jul 26.
12. Tyler MP, Watts AM, Perry ME, Roberts AH, McGrouther DA. Dermal cellular inflammation in burns. An insight into the function of dermal microvascular anatomy. *Burns*. 2001;27(5):433–8.

